

## Case Report

## Role of Hydrodistention and Intravesical Hyaluronic Acid in Treatment of Bladder Pain Syndrome: Case Report

Fanny R. Ridwan,<sup>1\*</sup> Bagus Baskoro,<sup>2</sup> Harrina E. Rahardjo<sup>1</sup>

<sup>1</sup>Department of Urology, Faculty of Medicine, Universitas Indonesia-  
dr. Cipto Mangunkusumo Hospital, Jakarta

<sup>2</sup>Department of Urology, Pasar Rebo Hospital, Jakarta

\*Corresponding author: fannyriana@gmail.com

Received 30 October 2022; Accepted 17 April 2023

<https://doi.org/10.23886/ejki.11.237.68>

### Abstract

Bladder pain syndrome (BPS) causes decreased mental and physical quality of life. The diagnosis and treatment of BPS must be made effective; however, the treatment of BPS was still not satisfactory for most patients. Two cases of BPS were presented to the urology clinic and were treated with a combination of hydrodistention and intravesical hyaluronic acid (HA) periodically. After 3-8 hydrodistention and hyaluronic acid instillation, the patients showed symptom improvement indicated by O'Leary Sant Questionnaire (symptom score 19-21 before treatment became 3-4 after treatment, problem score 8-16 before treatment became 0-2 after treatment), visual analogue scale (7-10 before treatment to 3-4 after treatment), and the global response assessment (GRA) scale were markedly improved. Both patients had glomerulations during cystoscopy, and the second had Hunner Lesion. A pathological examination of bladder biopsy specimens indicated acute and chronic inflammatory cell infiltration. The combination of hydrodistention and intravesical HA was beneficial for treating BPS in this study. Further study such as a clinical trial is needed to prove the efficacy and safety of this treatment.

**Keywords:** bladder pain syndrome, hydrodistention, intravesical hyaluronic acid.

## Peran Hidrodistensi dan Asam Hialuronat Intravesika pada Tata Laksana Sindrom Nyeri Kandung Kemih: Laporan Kasus

### Abstrak

Sindrom nyeri kandung kemih menyebabkan berkurangnya kualitas hidup secara mental dan fisik. Sindrom tersebut memerlukan diagnosis dan tata laksana yang tepat, namun selama ini tata laksana BPS memiliki angka kepuasan yang rendah. Pada laporan kasus ini, terdapat 2 pasien dengan BPS yang ditatalaksana dengan kombinasi hidrodistensi dan asam hyaluronat secara periodik. Setelah 3-8 hidrodistensi dan instilasi asam hyaluronat, pasien menunjukkan perbaikan gejala berdasarkan O'Leary Sant Questionnaire (skor gejala 19-21 sebelum terapi menjadi 3-4 setelah terapi, skor masalah 8-16 sebelum terapi menjadi 0-2 setelah terapi), visual analogue scale (dari 7-10 sebelum tata laksana menjadi 3-4 setelah tata laksana), dan skala global response assessment (GRA) berupa markedly improved. Pemeriksaan sistoskopi menunjukkan glomerulasi pada kedua pasien dan Hunner Lesions pada pasien kedua. Pemeriksaan histopatologi menunjukkan infiltrasi sel inflamasi akut dan kronik. Hidrodistensi dan asam hyaluronat intravesika memiliki efek yang baik untuk tata laksana sindrom nyeri kandung kemih. Dibutuhkan penelitian untuk mengetahui efikasi dari tata laksana kombinasi kedua jenis terapi.

**Kata kunci:** sindrom nyeri kandung kemih, hidrodistensi, asam hyaluronat intravesika.

## Introduction

Bladder pain syndrome (BPS) is a chronic disease that causes depression, anxiety, and an overall decreased mental and physical quality of life. It is associated with a variable impact on the quality of life, ranging from the inability to work to profound changes in sexual life. The incidence of BPS is quite high, affecting 2,7% of women and 1,9% of men in the population.<sup>1</sup>

The diagnosis and treatment of BPS must be made effective. However, most BPS cases are undiagnosed and often mistaken for overactive bladder (OAB) or chronic urinary infection. The symptoms of BPS often overlap with other gynecology or urinary diseases. Often more common differential diagnoses must be ruled out before BPS can be confirmed. Several tests, including urine culture and urinalysis, must be performed to rule out malignancy. Further tests such as urodynamics, cystoscopy/hydrodistention are conducted to differentiate OAB and BPS.<sup>2</sup>

Two cases of BPS were presented to the Urology Outpatient Clinic at Pasar Rebo Hospital. Both instances had Hunner Lesion and glomerulation in cystoscopic findings. Hunner Lesion is relatively rare in BPS cases, ranging from 5-20%.<sup>3</sup> Merwe et al,<sup>4</sup> reported glomerulation in more than 75% of bladder surface in 50% of cases of BPS. The rest had no glomerulation or only a few glomerulations.

The treatment of BPS includes hydrodistention and the intravesical instillation of hyaluronic acid (HA). Hydrodistention, which can be used as a diagnostic and therapeutic tool, is often the first choice in treating BPS. However, the inconvenience and high cost of hydrodistention do not make it viable as a singular treatment option.<sup>5</sup> Shao et al<sup>5</sup> studied the instillation of HA after hydrodistention to determine whether it would prolong the effect of hydrodistention in patients with bladder capacity less than 200 mL and 10% of the patients were unable to complete the treatment, 77,8% of patients achieved good improvement, and 12,2% failed to improve.<sup>5</sup> HA effectively prolongs the effect of hydrodistention significantly compared to the control and heparin

groups. Currently, no recommendation is available on using hydrodistention and intravesical instillation of HA combination therapy for treating BPS. In this case report, two cases of BPS were presented in Pasar Rebo Hospital with the good result using this combination.

## Case Presentation

### Patient 1

A 57-year-old woman presented to the urology clinic with complaints of frequency, dysuria, and intermittent gross hematuria for 23 years. The patient had been treated with antibiotics and analgesics, with no improvement of symptoms. There was no history of urinary tract infection (UTI), urinary tract tumor, pelvic radiation, and urinary stone. Cystoscopy, biopsy, and pathological examinations showed no bladder tumor or tuberculous cystitis. The patient also underwent a urodynamic examination. However, bladder capacity could not be determined because the patient was in pain when the bladder was filled and the procedure was stopped. Urinalysis and urinary tract ultrasonography were performed with unremarkable results. The patient was given antibiotics and analgesics but did not follow up any further. Eleven months after the first visit, the patient returned with worsening symptoms and underwent a cystoscopy. During the examination, hyperemic mucosa was found.

The patient was treated with bladder hydrodistention for a total of 3 times (13 months after the first cystoscopy and six months after the second cystoscopy) by performing an instillation of 100 cmH<sub>2</sub>O water for 2 minutes, repeated twice.<sup>6</sup> After the first hydrodistention procedure, glomerulation and Hunner Lesions were found in the posterior part of the bladder (Figure 1). A bladder biopsy was then carried out and the pathology examination showed acute and chronic inflammatory cells (Figure 2). The capacity of the bladder was measured three times, averaging 100 ml. Intravesical instillation of HA was performed after hydrodistention.

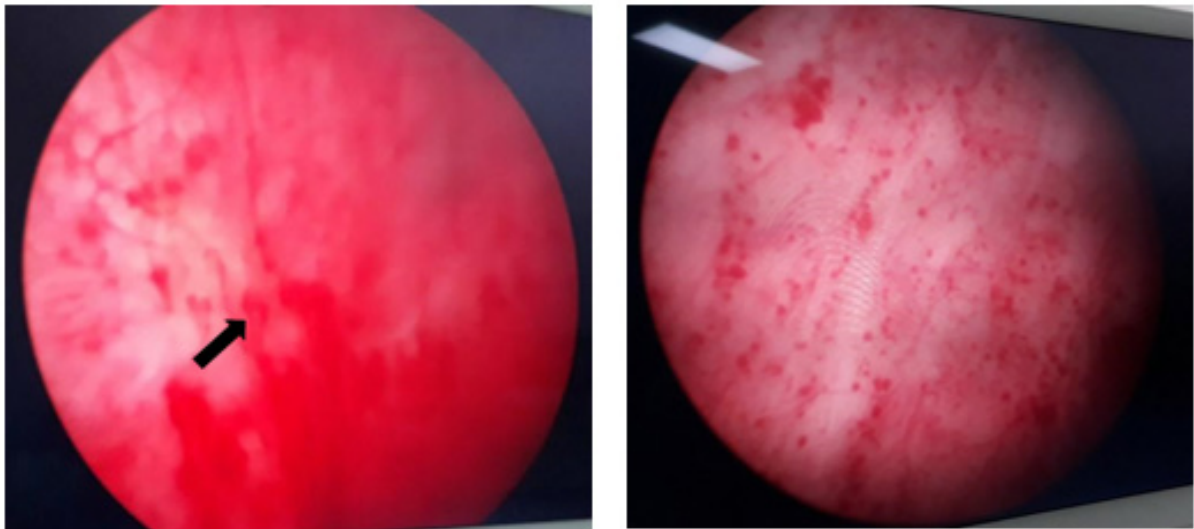


Figure 1. Second (a) and third (b) cystoscopy. Arrow show sign of glomerulation

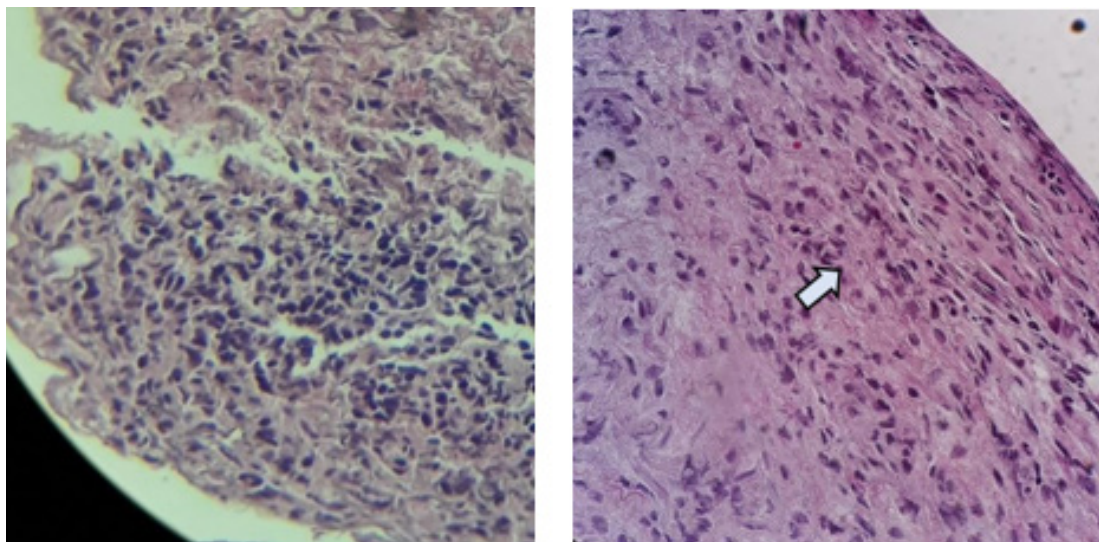


Figure 2. Pathological examination shows inflammatory cell infiltration, before (a) and after second cystoscopy and hydrodistention treatment (b).

The patient's symptoms were evaluated using O'Leary Sant questionnaire, Visual analogue score (VAS), and faces pain rating scale. O'Leary Sant questionnaire consists of 4 symptom questions (worst score: 20) and 4 problem questions (worst score: 16). VAS is the pain score with a maximum score of 10 that is subjectively chosen by the patient. Faces pain rating scale is a subjective pain scoring consisting of 1-5 by choosing face pictures that suit the patient's pain.

The patient came to the urology polyclinic with an initial O'Leary Sant symptom score of 19, problem score of 8, VAS of 7, and faces pain rating scale of 4. In the range of 24 months, two cystoscopy procedures and routine instillations of intravesical hyaluronic acid were performed. The

patient's symptom score was reduced to 2, the problem score was reduced to 0, and the VAS and faces pain rating scale was reduced to 0 after the second cystoscopy and hyaluronic acid instillation. However a month after, there was an increasing pain score (VAS 8, faces pain rating scale 3). The third hydrodistention was then performed, the pain scale was reduced to VAS 4, and the faces pain rating scale 2. The patient's symptoms were also assessed using global rating assessment (GRA) after every cystoscopy. The patient had a "markedly improved" score in GRA since the first cystoscopy until month 30. A summary of the symptoms' evaluation is described in Table 1. This patient has been diagnosed with type 2C BPS with glomerulation and inflammatory cells

infiltration in the biopsy specimen (Figure 2). The patient experienced no adverse effect during the

treatment. The COVID-19 pandemic hindered the patient from further consultation.

**Table 1. Patient 1 Symptoms' Evaluation**

Time	O'Leary Sant	VAS*	Faces **
Month 1 (initial presentation)	symptom: 19 problem: 8	7	4
Month 11 (after first cystoscopy)	symptom: 7 problem: 8	4	2
Month 23	symptom: 19 problem: 7	5	2
Month 25 (after second cystoscopy)	symptom: 2 problem: 0	0	0
Month 26	symptom: 5 problem: 0	8	3
Month 30 (after third cystoscopy)	symptom: 4 problem: 2	4	2

\* VAS: Visual analogue score

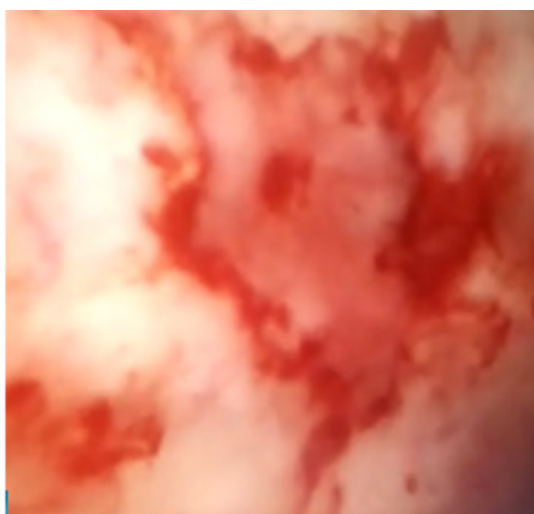\*\* Faces: pain rating scale

**Patient 2**

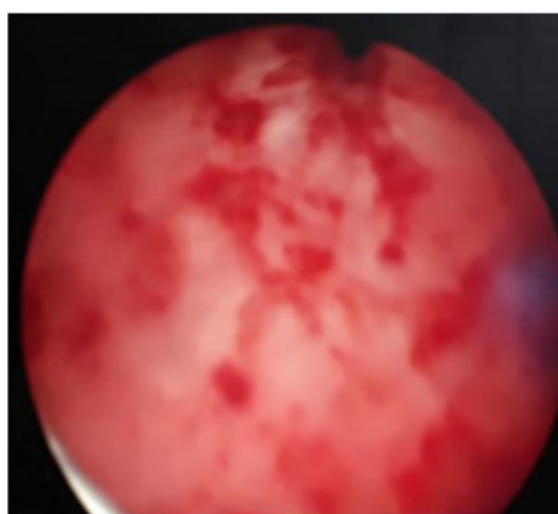
A 35-year-old woman presented to the urology clinic with complaints of urgency, nocturia, frequency, intermittent gross hematuria, and pain in the bladder, which increased with bladder filling. No history of urinary tract infection, urinary stone, or bladder tumor was reported.

Urinalysis and ultrasound of the urinary tract showed results within normal limits. Cystoscopy

was conducted and showed a hyperemic bladder wall, with evidence of bleeding. Hydrodistention was performed and during the procedure, Hunner lesions and glomerulations were found in the bladder wall (Figures 3a and 3b). As a result, the patient was classified as suffering from type 3C BPS. A biopsy of the bladder was carried out and the pathological examination showed acute and chronic inflammatory cells.

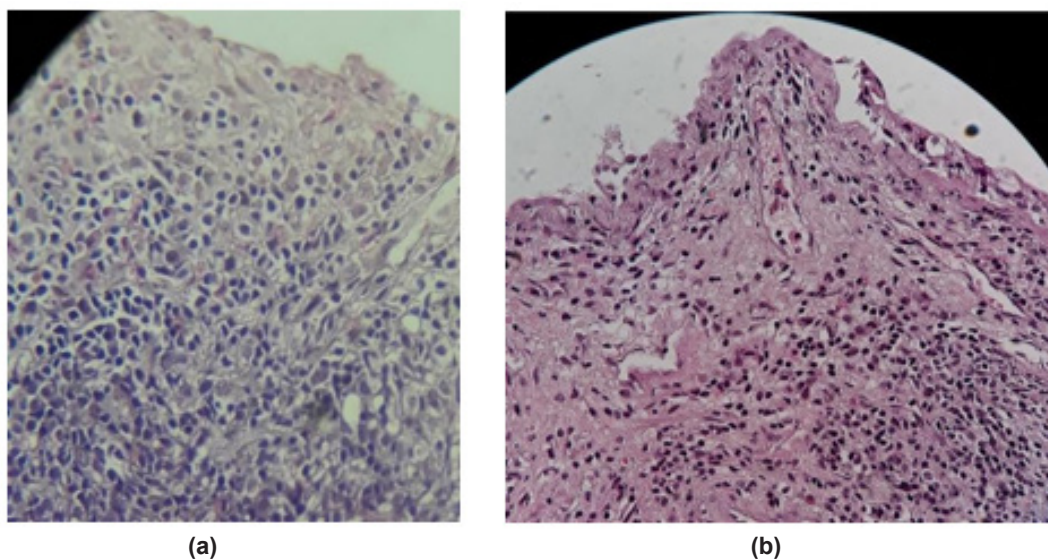


(a)



(b)

**Figures 3. a and 3b. Cystoscopy reveals Hunner Lesion (a) and glomerulations (b)**



**Figure 4.** Pathological examination shows chronic inflammatory cell infiltration, before (a) and after the fifth cystoscopy (b).

The patient received a total of 8 treatments of hydrodistention, followed by the instillation of HA in a span of 28 months. In the initial presentation, the patient came with O’Leary Sant symptom score of 21, problem score of 16, VAS 9-10, and faces pain rating scale of 5. After month 18, O’Leary Sant symptom score was reduced to 7, problem score 1, VAS 3-4, and faces pain rating scale 2. In month 21, the pain worsens with a VAS score of 6 and faces pain rating scale of 3. However, after the last treatment in month 28, the patient’s symptoms improved. The summary of the symptoms’ evaluation during follow-up is described in Table 2. There were no adverse effects due to the treatment reported by the patient. The patient no longer come for consultation since there were no more complaints.

**Table 2. Patient 2 Symptoms’ Evaluation**

Time	O’Leary Sant	VAS	Faces
Month 1	symptom: 21 problem: 16	9-10	5
Month 18	symptom: 7 problem: 1	3-4	2
Month 21	symptom: 8 problem: 7	6	3
Month 28	symptom: 3 problem: 0	3-4	3

\* VAS: Visual analogue score

\*\* Faces: pain rating scale

**Discussion**

BPS is a poorly understood disease in the field of urology. Berry et al<sup>7</sup> reported 3.3 – 7.9 million women in the US aged 18 years old or older presented with BPS symptoms, however, only 9.7% were diagnosed with BPS. The pathophysiology of BPS is still unclear, as there is no single pathogenesis. It is hypothesized that epithelial dysfunction, activation of mast cells, and sensory nerve up-regulation occur in BPS. Changes in the urothelial surface membrane permeability cause increased potassium movement, depolarization of bladder nerves, and activation of mast cells. Mastocytosis occurs in 30 – 65% of people with BPS.<sup>8</sup> Mast cells produce histamine, leukotrienes, prostaglandin, and tryptases.

BPS is usually diagnosed after all etiologies of bladder pain have been excluded, such as UTI, urolithiasis, bladder tumor, and neurogenic bladder. It is often underdiagnosed and therefore undertreated. BPS symptoms often overlap with other chronic pelvic pain symptoms, such as nonbacterial prostatitis and prostatodynia. Up to 70% of men with nonbacterial prostatitis and prostatodynia had the cystoscopic appearance of BPS.<sup>8</sup> It is also often underdiagnosed in people with overactive bladder syndrome and recurrent cystitis in women. Patients often present with bladder irritability and were treated with anticholinergics. Sant<sup>8</sup> revealed that 80% of patients who came with chronic pelvic pain to a gynecologist had a positive KCL test. BPS should be suspected in patients unresponsive to antibiotics and or who have a negative urine culture. The etiology of BPS

is unclear; therefore, the management is complex because no definitive treatment currently exists.

BPS is characterized as recurrent pelvic pain or discomfort, such as pressure, burning, or throbbing, for a duration of at least 4–6 weeks, and that increases with bladder filling and is relieved by micturition. Both patients presented in this report came to the urology clinic with the chief complaint of bladder pain syndrome. Both patients also complained of intermittent gross haematuria. The frequency was also experienced since the patients felt the pain had been relieved after urination. The patients came to the clinic after years of diagnostic and treatment trials, as well as chronic analgesic therapy, with no significant improvement in their symptoms.

BPS type 3 can lead to a small capacity bladder. Most patients with BPS have urgency symptoms with a bladder capacity of about 100 mL. A bladder capacity of less than 200 mL predicts the unresponsiveness of patients to medical therapy and the need for more aggressive treatment. In the first reported patient, the bladder capacity was 100 mL and in the second patient, the bladder capacity was 180 mL.

In the diagnostic evaluation of BPS, frequent volume charts can be useful in documenting the severity of the symptoms. The patients in this case report recorded bladder diaries that showed urinary frequency. Ultrasound was also performed to evaluate patients with urologic symptoms. Cystoscopy under anesthesia was carried out in patients with symptoms of BPS. The saline reservoir was placed 80 cm above the pubic symphysis and the bladder was filled due to gravity.<sup>9</sup> Following hydrodistention, a bladder biopsy was taken.

Results of the cystoscopy showed the presence of reddened mucosa, with small vessels radiating toward a central scar, which is known as a Hunner lesion. According to Mishra<sup>9</sup>, results from 250 cystoscopic examinations of people with BPS showed that Hunner lesions were rarely observed. In another study by Acar, Hunner Lesion occurred in 10-15% of BPS patients.<sup>10</sup> Another cystoscopic sign of BPS is glomerulations, which are pinpoint submucosal hemorrhages. In a study performed by Mishra, only about half of the patients had glomerulations in more than 75% of the area of the bladder mucosa.<sup>9</sup> The rest either had a few or did not show glomerulations at all. The abnormalities in cystoscopy results are correlated with worse daytime frequency, nocturia, and smaller bladder capacity under anesthesia.<sup>11</sup> The inflammation

features in the pathological examination can be seen in 24 – 76% of the patients with BPS 1.

Hydrodistention was carried out with cystoscopy as a diagnostic and therapeutic tool. The mechanism of hydrodistension in relieving pain is unclear, but it is thought that hydrodistension allows damaged nerve cells to break down and reconstruct.<sup>12</sup> The hydrodistension was performed under anesthesia with low pressure (60–80 mmH2O) for a short duration (<10 minutes).<sup>12</sup> Hydrodistension had shown symptomatic improvement in between 54% to more than 90% of the patients at various times (not exceeding 6–9 months).<sup>6</sup> According to the American Urological Association (AUA), cystoscopy under anesthesia with a short duration and low-pressure hydrodistention was performed as a third-line treatment after the first and second-line treatments had failed.<sup>13</sup> However, the efficacy of this treatment is not stated in the guideline. According to the European Association of Urology (EAU), hydrodistention could be used as a diagnostic tool, but its role as a therapeutic option is limited.<sup>15</sup> Hydrodistension was readily available in Pasar Rebo Hospital. In this case report, both patients had a good response to hydrodistention.

Hydrodistension provides visualization of the distended bladder to reveal the presence of glomerulations, which are a positive diagnostic, albeit non-specific, sign for BPS. Waterfall bleeding can be found after hydrodistention, which is associated with type 3 BPS. The AUA recommends hydrodistension for as long as 1–3 minutes with a water pressure of 60–80 cmH2O.<sup>13</sup> According to the National Institute of Diabetes and Digestive and Kidney Diseases (NIDDK), hydrodistention should be performed under anesthesia twice, with a water pressure of 80-100 cmH2O for as long as 1–2 minutes.<sup>6</sup> For the patients reported here, the hydrodistention procedure was performed using a pressure of 100 cmH2O. Symptom relief after hydrodistention was reported to occur for less than six months, with 20% of the patients achieving excellent improvement and 50–60% achieving partial improvement.<sup>3</sup> In the reported patients, improvement in the symptoms, especially bladder pain, occurred after hydrodistention.

Bladder epithelium is protected by glycosaminoglycan (GAG) such as HA. In the chronic inflammatory disorder of the bladder, such as cystitis, GAGs are lost from the outermost layer of the bladder mucosa. Damage to the urothelial lining of the bladder, consisting of the GAG layer in BPS patients, causes the exposure of urine into

the submucosal layer of the bladder. This triggers an inflammatory reaction and nerve stimulation, resulting in pain in these patients.<sup>15,18</sup> The GAG layer replenishment treatment such as HA reduces the chemotactic and phagocytic activity of leukocytes and the synovial membrane's permeability. HA increases the secretion of the GAG enzymes and restores normal GAG production.<sup>19</sup>

Replenishment of the GAG layer, via intravesical instillation of HA, has been widely used in the treatment of BPS. Intravesical HA (50 mL/120 mg) was administered once a week for six weeks, followed by twice a month for six months, and then once a month until 24 months after the start of the therapy.<sup>14</sup> This therapy provides symptomatic relief in 65% – 87% of patients, but symptoms recur in 47% of patients within 3–6 months. The repeated dose reduces symptoms in 53% of BPS patients.<sup>14</sup>

The dosage of HA is 40 mg of a 0.1% solution, administered weekly for 4–6 weeks, followed by monthly instillation for five months. A good response was seen in 30-71% of patients. However, the effect decreases in the maintenance period, and the efficacy of HA is still unproven in controlled and blinded clinical trials.<sup>11</sup> The instillation of HA prolonged the effect of hydrodistention in severe BPS.<sup>5</sup> Patients that were given intravesical HA showed better improvement on average after six months post-hydrodistention, compared to the patients that were given heparin as a control. Intravesical instillation of HA is a less invasive choice of treatment. However, the availability of an intravesical HA regimen was limited in our hospital.

According to the guidelines published by the European Association of Urology, the efficacy of intravesical HA was confirmed in one meta-analysis. However, most of the included studies were not randomized.<sup>15</sup> According to the American Urological Association guidelines, hydrodistention was offered as a third-line treatment after previous attempts had failed to improve the patient's quality of life.<sup>13</sup> Compliance is one important factor in the success of this treatment regimen. The first patient reported in this study tended to delay treatment when symptoms had improved, while the second patient was more compliant with therapy.

Pyo et al,<sup>16</sup> reported that intravesical sodium hyaluronate can reduce the destruction of the glycosaminoglycan (GAG) layer in the bladder and be used for as long as 20 years. However, the study had a small sample size and was not well. HA can be given as much as 40 mg/50 mL, up to 4 times per week, and repeated once a month.<sup>17</sup>

In this case report, both patients were given hydrodistention and HA instillation with good compliance. The patients had significant symptom improvement after treatment. However, BPS is a chronic disease with possible flare episodes.<sup>1</sup> The first patient had a vast improvement in her symptoms after 25 months, but the symptoms got worse in the next month. There are several factors that might affect this patient's symptoms, such as diet, allergy, and psychological stress.<sup>11</sup> A careful history taking must be performed to evaluate the etiology. The patient also has to be educated about the food/drink that might trigger the symptoms. If the patient has an allergy, it has to be treated.

During cystoscopy, both patients showed glomerulation, in patient 2 there was also Hunner lesion during hydrodistention. According to ESSIC classification, the first patient had type 2C BPS (without Hunner lesion) and the second patient had 3C BPS (with Hunner lesion). According to the AUA guideline, cystoscopy under anesthesia with low-pressure hydrodistention could make the identification of Hunner lesion easier because of the cracking and mucosal bleeding. If Hunner lesion during cystoscopy was detected, hydrodistention was recommended as treatment. The AUA also recommend injection of triamcinolone and fulguration. If the treatment fails, Cyclosporine A (CyA) oral may be given in patient with Hunner lesion.<sup>13</sup> In this case report, despite this BPS type difference, hydrodistention and hyaluronic acid provide the same symptom relief in these patients.

In patient with BPS, the bladder wall could be very thin. Therefore there is a possibility of bladder rupture during hydrodistention. In study by Shao<sup>5</sup>, 2 of 44 patients had bladder rupture during treatment. The patients then had indwelling catheter for 1 week and had good recovery. Pyo et al<sup>16</sup> stated there was mild adverse effect during intravesical instillations of HA, such as UTI, temporary worsening symptoms, and adverse effects related to catheterization. There was no serious adverse effect during the study. The HA instillations were tolerated by patients and should be done with antibiotics and careful catheterization.

In Indonesia, diagnostic modalities and treatment options for BPS are still limited. Resources required to rule out diagnoses, such as urodynamics, are not available in most hospitals. Hydrodistention is possible in hospitals with urologists, but not in more rural areas, where urologists or endoscopic equipment are lacking. The choice of intravesical therapy is also limited;

most healthcare professionals use intravesical HA since it is the only treatment available in Indonesia for interstitial BPS. Other therapeutic agents such as pentosan polysulfate, which the EAU and AUA strongly recommend, are not yet available in Indonesia.

### Conclusion

In this case report, two patients with BPS were treated with a combination of hydrodistension and intravesical HA. Both patients showed a good response to the therapy with good overall outcomes. Further studies on the combination of this therapy are needed to assess their effectiveness in treating BPS in the population.

### References

- Moldwin RM, Philip M, Hanno PM. Interstitial cystitis/bladder pain syndrome and related disorders. In: Wein AJ, Partin AW, Peter CA. Campbell-Walsh-Urology. 12th ed. Philadelphia: Elsevier; 2021. p.1224-7.
- Macdiarmid SA, Sand PK. Diagnosis of interstitial cystitis/bladder symptoms. *Rev Urol.* 2007;9:9–16.
- Han E, Nguyen L, Sirls L, Peters K. Current best practice management of interstitial cystitis/bladder pain syndrome. *Ther Adv Urol.* 2018;197–211. doi: 10.1177/1756287218761574.
- van de Merwe JP, Nordling J, Bouchelouche J, Bouchelouche K, Cervigni M, Daha LK, et al. Diagnostic criteria, classification, and nomenclature for painful bladder syndrome/interstitial cystitis: an ESSIC proposal. *Eur Urol.* 2008;53:60-7. doi: 10.1016/j.eururo.2007.09.019.
- Shao Y, Shen ZJ, Rui WB, Zhou WL. Intravesical instillation of hyaluronic acid prolonged the effect of bladder hydrodistention in patients with severe interstitial cystitis. *Urology.* 2010;75:547–50. doi: 10.1016/j.urology.2009.09.078.
- Ens G, Garrido GL. Role of cystoscopy and hydrodistention in the diagnosis of interstitial cystitis/bladder pain syndrome. *Transl Androl Urol.* 2015;624–8. doi: 10.3978/j.issn.2223-4683.2015.09.04.
- Berry SH, Elliott MN, Suttrop M, Bogart MN, Stoto MA, Eggers P, et al. Prevalence of symptoms of bladder pain syndrome/interstitial cystitis among adult females in the United States. *J Urol.* 2011;540–4. doi: 10.1016/j.juro.2011.03.132.
- Sant GR. Diagnosis of interstitial cystitis. *Rev Urol.* 2002; 9–15. doi: 10.3109/9780203908938-17.
- Mishra NN. Clinical presentation and treatment of bladder pain syndrome/interstitial cystitis (BPS/IC) in India. *Transl Androl Urol.* 2015; 512–23. doi: 10.3978/j.issn.2223-4683.2015.10.05.
- Acar Ö. Cystoscopic evaluation and clinical phenotyping in interstitial cystitis/bladder pain syndrome. *J Turk Ger Gynecol Assoc.* 2019;117–22. doi: 10.4274/jtgga.galenos.2018.2018.0102.
- Moldwin RM, Philip M, Hanno PM. Interstitial cystitis/bladder pain syndrome and related disorders. In: Alan JW, Alan WP, Peters CA. Campbell-Walsh Urology. 11th ed. Philadelphia: Elsevier; 2016. p.1230-4.
- Colaco M, Evans R. Current guidelines in the management of interstitial cystitis. *Transl Androl Urol.* 2015;4:677–83. doi: 10.3978/j.issn.2223-4683.2015.11.03.
- Clemens JQ, Erickson DR, Varela NP, Lai HH. Diagnosis and treatment of interstitial cystitis/bladder pain syndrome. *J Urol.* 2022;208:34-42. doi: 10.1097/JU.0000000000002756.
- Özkıdık M. Assessment of long-term intravesical hyaluronic acid, chondroitin sulfate and combination therapy for patients with bladder pain syndrome. *Cent European J Urol.* 2019;270–5. doi: 10.5173/ceju.2019.0007.
- Engeler D, Baranowski AP, Berghmans B, Birch J, Borovicka J, Cottrell AM. EAU Guidelines on Chronic Pelvic Pain. Arnhem: EAU Guidelines Office; 2022.
- Pyo JS, Cho WJ. Systematic review and meta-analysis of intravesical hyaluronic acid and hyaluronic acid/chondroitin sulfate instillation for interstitial cystitis/painful bladder syndrome. *Cell Physiol Biochem.* 2016;39:1618–25. doi: 10.1159/000447863.
- Rahardjo HE, Santoso BI, Tjahjodjati, Daryanto B, Sigumonrong YH, Priyatini T, et al. Panduan tata laksana sindrom nyeri kandung kemih. Jakarta: Ikatan Ahli Urologi Indonesia (IAUI); 2019. Indonesian.
- Cho YS. Interstitial cystitis / bladder pain syndrome: a urologic mystery. *Int Neurourol J.* 2016;3-4. doi: 10.5213/inj.1620edi.002.
- Cervigni M. Interstitial cystitis/bladder pain syndrome and glycosaminoglycans replacement therapy. *Transl Androl Urol.* 2015;4:638–42. doi: 10.3978/j.issn.2223-4683.2015.11.04.